

# Efficacy of a novel self-assembling peptide hemostatic gel as rescue therapy for refractory acute gastrointestinal bleeding

## Authors

Germana de Nucci<sup>1</sup>, Raffaella Reati<sup>1</sup>, Ilaria Arena<sup>2</sup>, Cristina Bezzio<sup>2</sup>, Massimo Devani<sup>2</sup>, Cristina della Corte<sup>2</sup>, Daniela Morganti<sup>1</sup>, Enzo Domenico Mandelli<sup>1</sup>, Barbara Omazzi<sup>2</sup>, Davide Redaelli<sup>1</sup>, Simone Saibeni<sup>2</sup>, Marco Dinelli<sup>3</sup>, Gianpiero Manes<sup>1,2</sup>

## Institutions

- 1 Gastroenterology and Endoscopy Unit, Aziende Socio Sanitaria Territoriale Rhodense – Garbagnate Milanese, Milan, Italy
- 2 Gastroenterology and Endoscopy Unit, Aziende Socio Sanitaria Territoriale Rhodense – Rho Hospital, Milan, Italy
- 3 Endoscopy Unit, San Gerardo Hospital, Monza, Italy

submitted 23.12.2019

accepted after revision 10.3.2020

## Bibliography

DOI <https://doi.org/10.1055/a-1145-3412>

Published online: 2020 | Endoscopy

© Georg Thieme Verlag KG Stuttgart · New York

ISSN 0013-726X

## Corresponding author

Germana de Nucci, MD, Gastroenterology and Digestive Endoscopy Unit, ASST Rhodense, viale Forlanini 95, Garbagnate Milanese, Milan, Italy  
 Fax: +39-02-994302905  
[germanadenucci1@gmail.com](mailto:germanadenucci1@gmail.com)

## ABSTRACT

**Background** Acute gastrointestinal bleeding (AGIB) results in significant morbidity and mortality. Topical hemostatic products have been developed for endoscopic use to

help in the management of difficult bleeding. Our aim was to demonstrate the ease of use, safety, and efficacy of PuraStat, a novel hemostat, to control AGIB.

**Methods** We describe 77 patients (41 men) who were treated for acute upper and lower AGIB in a 2-year period. In 50 patients, bleeding occurred as a complication of a previous endoscopic procedure, predominantly endoscopic mucosal resection (EMR) and endoscopic retrograde cholangiopancreatography (ERCP); however, in the other 27 patients, it derived from peptic ulcers, angiodysplasia, cancers, and surgical anastomoses. Bleeding was spurting in 13 of the 77 patients and oozing in 64. PuraStat was used after the failure of at least two conventional hemostatic methods.

**Results** A mean of 2.6 conventional hemostatic methods had been attempted prior to the application of PuraStat. PuraStat achieved successful hemostasis in 90.9% of patients. In 41 patients, once hemostasis was obtained with PuraStat, endoscopists further stabilized hemostasis by using at least one additional method. Recurrence of bleeding was observed in eight patients (10.4%). In 16 patients with intraprocedural bleeding, it was possible to complete the procedures (14 EMR, 2 ERCP) after PuraStat hemostasis. No adverse events related to PuraStat were recorded.

**Conclusions** PuraStat is feasible, safe, and effective in controlling different types of gastrointestinal hemorrhage after failure of conventional hemostatic methods. Its application also does not hinder continuing endotherapy.

## Introduction

Acute gastrointestinal bleeding (AGIB) is a common cause for hospitalization and is associated with significant morbidity and mortality [1]. Stable hemostasis can be achieved in more than 90% of cases of upper and lower AGIB using endoscopy by combining injection, and thermal and mechanical methods [1,2]. Depending on the cause of the bleeding and its anatomical location, management of AGIB can, however, be challenging. In such cases, a high level of technical expertise is required as life-threatening bleeding can occur at any time, and less skilled endoscopists may have difficulty in achieving endoscopic hemostasis [2].

In order to overcome these difficulties, topical hemostatic agents for endoscopic use have been developed in recent years. Currently, three hemostatic agents are available for endoscopic use [3]: TC-325 (Hemospray, Cook Medical, Winston-Salem, North Carolina, USA) [4]; EndoClot (EndoClot Plus, Inc., Santa Clara, California, USA) [5]; and Ankaferd Blood Stopper (Ankaferd Health Products Ltd., Turkey) [6]. Despite differences in their chemical composition, all three agents work in a similar way. Briefly, when the agents come into contact with bodily fluids, they immediately convert from a powder into a gel to form a stable mechanical barrier that can seal the bleeding focus and enhance clot formation, inducing hemostasis.

Several studies have demonstrated that powders are effective in achieving hemostasis, even if they are applied in a non-targeted manner [7–9]. However, despite the excellent short-term outcomes, these products also have drawbacks. First, because of their opaque nature, these products can hinder the view through an endoscope once the powder has been applied to the lesion. Second, the application of the powder may be complicated by its dispersion and/or premature gel formation, which may result in clogging of the catheter or obscuration of the endoscopic lens. These potential complications, together with the loss of adhesion and rapid dissolution of the gel over the time [10], may explain the high rate of recurrent bleeding that has been described, occurring in up to 49% of patients [7].

PuraStat (3-D Matrix Europe SAS, France) is a novel synthetic medical device product, licensed as a CE-marked surgical hemostatic agent. PuraStat consists of a fully synthetic viscous peptide solution that forms a transparent hydrogel at neutral pH. Once PuraStat is applied to a bleeding area, it will rapidly form a hydrogel barrier to produce hemostasis. The contact between PuraStat and bodily fluids allows for the formation of a three-dimensional scaffold structure, rapidly covering the point of bleeding and providing a physical barrier and surface under which coagulation occurs and hemostasis is obtained.

PuraStat has several unique features that distinguish it from existing products. It is a synthetic inert material with no risk of contamination from a biological source. Furthermore, the transparent adherent barrier that is formed does not obscure the view through the endoscope and allows the endoscopic procedure to be continued following hemostasis. Additionally, *in vitro* models and animal studies have evaluated its hemostatic efficacy, as well as its capability in enhancing tissue regeneration [11, 12], and data in cardiovascular and general surgery support its use in humans [13], but also highlight its limited efficacy where there is forceful arterial bleeding that can dislodge the gel and result in loss of the hemostatic effect.

There are a few published papers available on the use of PuraStat in AGIB; however, they are focused on the treatment of intraprocedural bleeding and delayed bleeding in endoscopic mucosal resection (EMR) or endoscopic submucosal dissection (ESD) [14–17]. In general, the role of hemostatic powders has not yet been clearly defined in the management of AGIB, but it is conceivable that, mainly due to their costs, they should be used as a second-line therapy once conventional hemostatic treatments have failed [1]. We herein report our experience with PuraStat over a 2-year period in patients with both upper and lower AGIB who were not responding to standard endoscopic treatments.

## Methods

Our study is a retrospective, observational, open-label, consecutive case series. The study was approved by the local institutional review board.

PuraStat has been available in our three hospitals since November 2017. Because of its cost and the limited clinical data available in the literature, its use in our hospitals has been restricted to the salvage treatment of upper and lower AGIB that

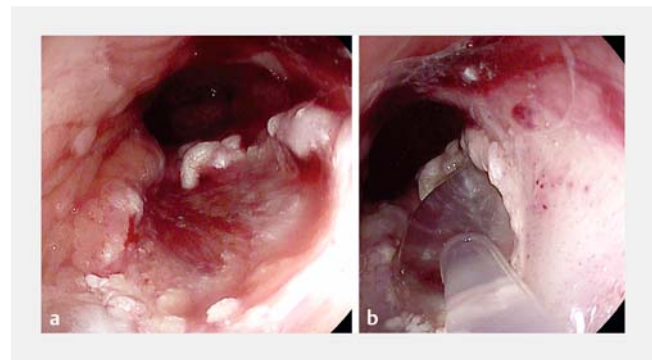
remained unresolved following the application of at least two standard hemostatic methods. Its only permitted use as a first-line therapy was for bleeding in difficult anatomical conditions that made standard hemostatic methods impractical, such as for lesions behind curvatures or folds, where the endoscope position was not stable enough to perform targeted hemostasis, or when bleeding appeared to be diffuse and a definite bleeding source could not be recognized within a large area of bleeding, such as in bleeding tumors.

In our study, we have retrospectively analyzed clinical data from adult patients with upper and lower AGIB treated with PuraStat according to the aforementioned indications. The exclusion criteria were the use of PuraStat as a primary hemostatic agent or prophylactically to prevent delayed bleeding after polypectomy, EMR, or ESD.

Our main aim was to assess the clinical success of PuraStat, meaning its ability to achieve immediate hemostasis. The secondary outcome assessed was the recurrence of bleeding within 7 days of PuraStat therapy, defined as the occurrence of clinical signs of bleeding (hematemesis, melena, or hematochezia; a drop in hemoglobin >2 g/dL or the need for the transfusion of four or more units of blood; or hemodynamic instability) and the presence of fresh blood or stigmata of recent bleeding at the treated site on endoscopic investigation. We also evaluated the ability of the endoscopists to continue the endoscopic procedure, if indicated, after having achieved primary hemostasis with PuraStat. The occurrence of adverse events (AEs) following endoscopic therapy was also recorded.

## PuraStat application

PuraStat is supplied in a prefilled syringe, available in 1-mL, 3-mL, and 5-mL volumes, and is applied using a custom endoscopic catheter, compatible with a 2.8-mm channel, that is introduced through the biopsy channel of the endoscope (► Fig. 1). To ensure the optimal adhesion of the gel, the tip of the catheter is positioned in such a way as to allow the gel to slide by gravity onto the lesion. The gel is applied starting from the distal side of the lesion, moving proximally. During



► Fig. 1 Endoscopic images of bleeding that occurred after cap-assisted endoscopic mucosal resection of dysplastic Barrett's esophagus showing: **a** persisting ooze in spite of epinephrine injection and argon plasma coagulation treatment; **b** the application of PuraStat through the delivery catheter.

► **Table 1** Demographic and clinical characteristics of the 77 patients treated with PuraStat as rescue therapy for refractory acute gastrointestinal bleeding (AGIB).

	Total cohort	Spontaneous AGIB (n=27)	Post-procedural AGIB (n=50)	P value Odds ratio (95% confidence interval)
Age, mean (SD); [range]	69.5 (9.6); [45–88]	75.6 (8.9); [51–88]	66.0 (8.2); [45–82]	$P < 0.001$
Sex, male/female, n	41/36	15/12	26/24	$P = 0.47$ OR 1.3 (0.5–3.1)
Anticoagulation, yes/no	14/63	9/18	5/45	$P = 0.02$ OR 0.24 (0.07–0.8)
Platelet inhibition, yes/no	35/42	17/10	18/22	$P = 0.21$ OR 0.5 (0.2–1.4)
NSAID, yes/no	10/67	7/20	3/47	$P = 0.03$ OR 0.2 (0.05–0.8)
Upper/lower AGIB	41/36	24/3	17/33	$P < 0.001$ OR 15.5 (4.1–59.0)

OR, odds ratio; NSAID, nonsteroidal anti-inflammatory drugs.

the application, endoscopists try to maintain the scope in a stable position and avoid injecting water or aspirating to prevent gel dispersion (► **Video 1**).

After hemostasis had been achieved by PuraStat, additional hemostatic methods were applied if there were high risk stigmata, such as when there had been previous spurting bleeding or there was a visible vessel, as stated by current guidelines [1]. The hemostatic techniques were decided by the endoscopist according to the characteristics of the lesion.

### Statistical analysis

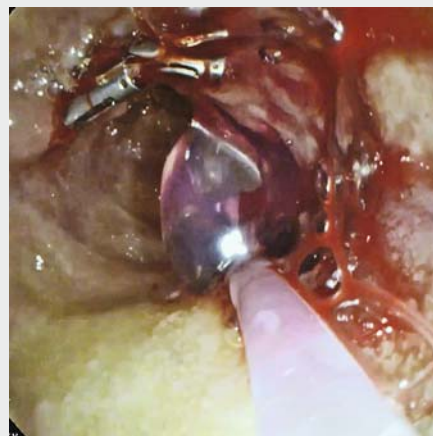
Patient data were collected prospectively in a database developed with Microsoft Excel. Collected data were analyzed retrospectively. Technical success was defined as the correct application of PuraStat on the bleeding lesion, meaning the complete coverage of the lesion by the gel. Clinical success was defined by the immediate achievement of hemostasis.

Data were analyzed using the Statistical Package for Social Sciences for Windows (SPSS software v.15.0, Chicago, Illinois, USA). The descriptive statistics used included the determination of mean value and standard deviation (SD) for the continuous variables, and percentages and proportions for the categorical variables. Statistical analysis was performed using chi-squared and Student's *t* test, when appropriate. The odds ratio (OR) for quantifying the statistical difference between the dichotomous variables was also calculated. Statistical significance was defined as a two-sided *P* value  $< 0.05$ .

### Results

► **Table 1** summarizes the patients' demographic and clinical data. The etiology, location, and characteristics of the bleeding are summarized in ► **Table 2**.

In a 2-year period (November 2017–November 2019), we treated 107 patients with PuraStat. We excluded 25 patients in whom PuraStat was used prophylactically to reduce the risk of delayed bleeding when undergoing EMR or ESD, and five patients in whom PuraStat was used inappropriately as first-line treatment of their bleeding lesions. The remaining 77 patients (41 men; mean age 69.5 years, range 45–88 years) were treated with PuraStat for AGIB as a rescue treatment according to the inclusion criteria and were included in the study. Of these



► **Video 1** Preparation of PuraStat and its use in two patients with upper and lower gastrointestinal bleeding. PuraStat was used after the failure of two other hemostatic techniques; in both cases, after the bleeding was stopped, hemostasis was stabilized with the application of clips.  
Online content viewable at:  
<https://doi.org/10.1055/a-1145-3412>

► **Table 2** Characteristics of the bleeds and the treatments performed to manage them.

Location	Cause of bleeding, n	Type of bleeding, n	Rebleeding, n	Treatments before PuraStat, n	Treatments after PuraStat, n
Esophagus	Post-EMR 4	Spurting 1	0	Adrenaline 1, APC 1, clipping 1	None
		Oozing 3	0	Adrenaline 3, APC 3, clipping 1	APC 2, clipping 1
Stomach	Ulcer 7	Spurting 2	1	Adrenaline 2, APC 2, clipping 1	None
		Oozing 5	0	Adrenaline 5, APC 4, clipping 3	APC 3, clipping 2
	Angiodysplasia 1	Spurting 0	N/A	N/A	N/A
		Oozing 1	0	Adrenaline 1, APC 1, clipping 1	APC 1
	Cancer 3	Spurting 0	N/A	N/A	N/A
		Oozing 3	2	Adrenaline 3, APC 3	APC 1, clipping 1
	Post-EMR 3	Spurting 1	0	Adrenaline 1, APC 1, forceps 1, clipping 1	APC 1
		Oozing 2	0	Adrenaline 2, APC 2, clipping 2, forceps 1	APC 1, clipping 1
Duodenum	Ulcer 12	Spurting 3	1	Adrenaline 3, APC 2, OTS clipping 1	APC 1
		Oozing 9	1	Adrenaline 9, APC 8, clipping 5	APC 5, clipping 3
	Angiodysplasia 1	Spurting 0	N/A	N/A	N/A
		Oozing 1	0	Adrenaline 1, APC 1, clipping 1	APC 1
	Post-EMR 4	Spurting 0	N/A	N/A	N/A
		Oozing 4	1	Adrenaline 4, APC 3, clipping 2, forceps 1	APC 1, clipping 2, OTS clipping 1
	Post-ERCP 5	Spurting 1	0	Adrenaline 1, SEMS 1, clipping 1	None
		Oozing 4	0	Adrenaline 4, APC 2, SEMS 4, clipping 2	Clip 1
Pseudocyst	EUS-guided stenting 1	Spurting 1	0	None	None
		Oozing 0	N/A	N/A	N/A
Colon	Post-EMR 32	Spurting 4	0	Adrenaline 4, APC 4, forceps 3, clipping 2	APC 1, clipping 1
		Oozing 28	0	Adrenaline 28, APC 22, forceps 6, clipping 15, OTS clipping 2	APC 7, clipping 7, OTS clipping 1
	Cancer 2	Spurting 0	N/A	N/A	N/A
		Oozing 2	2	Adrenaline 2, APC 2	None
	Anastomotic 1	Spurting 0	N/A	N/A	N/A
		Oozing 1	0	Adrenaline 1, APC 1, clipping 1, OTS clipping 1	OTS clipping 1
	Prostate biopsy 1	Spurting 0	N/A	N/A	N/A
		Oozing 1	0	Adrenaline 1, APC 1, clipping 1	Clip 1

EMR, endoscopic mucosal resection; APC, argon plasma coagulation; NA, not available; OTS, over-the-scope; ERCP, endoscopic retrograde cholangiopancreatography; SEMS, self-expanding metal stent; EUS, endoscopic ultrasound.

77 patients, 36 presented with lower AGIB and 41 with upper AGIB. Bleeding was spurting in 13 patients and oozing in 64.

The majority of patients (50/77) presented with iatrogenic bleeding, while in the remaining 27 patients bleeding occurred from peptic ulcers (duodenal,  $n=12$ ; gastric,  $n=7$ ), cancers (gastric,  $n=3$ ; colonic,  $n=2$ ), angiodysplasia (gastric,  $n=1$ ; duodenal,  $n=1$ ), and a post-surgical rectal anastomosis ( $n=1$ ).

In the 50 patients with iatrogenic bleeds, the bleeding occurred mainly after EMR ( $n=43$ : colonic,  $n=32$ ; esophageal,  $n=4$ ; duodenal,  $n=4$ ; gastric,  $n=3$ ); papillary bleeding after sphincterotomy ( $n=5$ ); rectal bleeding following transrectal prostate biopsy ( $n=1$ ), and acute bleeding inside a pseudocyst after endoscopic-ultrasound guided placement of a lumen-apposing metal stent ( $n=1$ ). In 16/50 patients, bleeding was intraprocedural, either while EMR was being performed (colonic,  $n=9$ ; esophageal,  $n=2$ ; gastric,  $n=2$ ; duodenal,  $n=1$ ) or during sphincterotomy ( $n=2$ ). In the remaining 34 patients, bleeding occurred as a delayed complication: within 24 hours after the procedure was performed ( $n=30$ ) and within 48 hours ( $n=4$ ).

In all except one patient, PuraStat was used as a salvage therapy after the failure of at least two standard hemostatic methods. For the patient with pseudocyst bleeding, PuraStat was applied into the pseudocyst cavity without any other previous attempts at hemostasis.

Technical success was measured (i. e. the correct application of PuraStat on the bleeding lesions) and was achieved in all patients. The application was performed easily in all patients, with no catheter clogging or kinking. On average, 3.7 mL (range 3–6 mL) of PuraStat was used to achieve hemostasis.

Immediate hemostasis (i. e. clinical success) was obtained in 70/77 patients (90.9%). PuraStat failed to stop seven spurting bleeds: two from duodenal ulcers, two from gastric ulcers, and three that developed after EMR (gastric, duodenal, colonic [ $n=1$  each]). However, in five of these patients, PuraStat application was able to slow the spurting bleeding to an ooze, which allowed hemostasis to be achieved with the addition of repeated argon plasma coagulation (APC) treatment.

Prior to PuraStat application, a mean of 2.6 hemostatic procedures (range 2–4) had been attempted: adrenaline injection was the first-line therapy in all patients but one (the patient with pseudocyst bleeding), while through-the-scope clipping was performed in 40 patients, APC in 63, diathermy via coagulation forceps in 12, biliary stenting in five, and over-the-scope clipping in four.

Following PuraStat application, the endoscopic visibility was judged to be adequate to continue endotherapy in all patients. In all of the 16 patients with intraprocedural bleeding, the therapeutic procedures (14 EMR and 2 ERCP) were completed in the same session. In 41 of 60 patients with either spontaneous or post-procedural bleeding, endoscopists were able to reinforce the hemostasis by applying one or more additional hemostatic methods: 26 using APC, 20 using through-the-scope clipping (► **Fig. 2**), and three using over-the-scope clipping.

In the patient with intracystic bleeding, PuraStat application remained the only therapy; hemostasis was obtained after the application of 6 mL of product. In this patient, a second-look endoscopy was performed after 3 days and the cyst cavity was

explored through the stent revealing granulation tissue. The stent was removed 2 weeks later.

Recurrence of bleeding within 1 week of hemostasis was observed in eight patients (10.4%): duodenal ulcer ( $n=1$ ), gastric ulcer ( $n=2$ ), post-EMR gastric bleeding ( $n=2$ ), gastric cancer ( $n=2$ : adenocarcinoma and leiomyosarcoma [ $n=1$  each]), and colon cancer ( $n=1$ ). PuraStat was applied again in all of these patients, with stable hemostasis being achieved in 6/8 patients. Only the two patients with gastric cancer underwent surgery for uncontrolled bleeding.

No adverse events potentially related to the use of PuraStat were registered.

## Discussion

This present study demonstrates the ease of use, safety, and efficacy of PuraStat in achieving hemostasis in bleeding from various sources, both in the upper and lower GI tract.

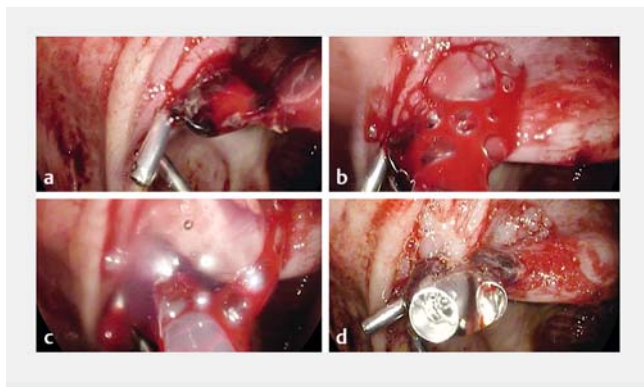
To our knowledge, our study represents the largest case series evaluating the use of PuraStat as a rescue therapy after the failure of standard hemostatic methods. The efficacy of PuraStat in primary hemostasis was 90% in our study, which confirms the results of previous studies where the product was used as a single agent to manage post-EMR/ESD bleeding [14, 15]. The immediate hemostatic effect of PuraStat has shown similar results to those of other powders, including TC-235, which showed a technical success rate higher than 90% in bleeding from various sources [3–5, 7]. However, the great advantage of PuraStat over other products is the very low rebleeding rate of approximately 10%, compared with data from the literature that show hemostatic powders have rebleeding rates between 12% and 49% [7, 18–22].

In recent years, hemostatic powders have been introduced into endoscopy to manage challenging GI bleeds, such as diffuse and neoplastic bleeds, as well as bleeds occurring in difficult to reach anatomical locations. These products work even if applied in a non-targeted manner but their physical characteristics may limit their applicability and efficacy because they are supplied as a powder and are opaque.

PuraStat is a novel hemostatic agent, recently introduced into endoscopy, that has several features which are likely to overcome the limits of the previous topical hemostatic agents: it is a transparent gel, which is ready to use and easy to apply; moreover, it forms a very stable coating on the mucosa that is likely to promote an immediate and durable hemostatic effect.

As a transparent gel, PuraStat does not obscure the view of the mucosa and allows endoscopists to continue endotherapy, either by completing the endoscopic resection [14] or by applying additional hemostatic modalities. In our study, after PuraStat hemostasis, endoscopists were able to apply one or more additional techniques to stabilize hemostasis in all of the 41 patients in whom they recognized high risk stigmata (► **Video 1**). Only four of these patients developed recurrent bleeding.

From the theoretical perspective, topical hemostats may work very well in achieving primary hemostasis [3–7], but their effect is unlikely to be durable owing to the constant peristalsis and mucus production in the environment of the GI tract. The



► **Fig. 2** Endoscopic images of bleeding that occurred after endoscopic mucosal resection of a flat lesion in the cecum showing: **a** oozing bleeding that persisted in spite of clipping; **b** the application catheter in place close to the bleeding lesion; **c** the application of PuraStat, which stopped the bleeding; **d** the application of a further clip that achieved stable hemostasis, which was possible owing to the transparent nature of PuraStat.

recurrence of bleeding in patients treated with other topical products has been described as being very high when used as a single agent and varies between 12% and 49% for TC-235 [7, 18–22]. The very low rebleeding rate recorded in our series may be attributed to the ability of the endoscopists to apply additional hemostatic methods in patients at high risk of rebleeding. In the same way, it is conceivable that all topical hemostats would be better used as a bridging method primarily to stop the bleeding and allow more comfortable management with more durable methods, such clipping or APC (► **Video 1**). Their use may thus resemble that of adrenaline injection, which, as suggested by current guidelines, should always be followed by a further mechanical or thermal method [1].

Furthermore, the transparent nature of PuraStat is a key element for endoscopists in its ease of use. Of note, since PuraStat application did not obscure the endoscopic view, we were able to complete the endoscopic procedures (14 EMR and 2 ERCP) in all 16 patients in whom an intraprocedural bleeding occurred. Our data confirm those of the study by Subramanian et al. [14], in which PuraStat used as a single hemostatic method stopped the bleeding in 75% of the 64 cases of intraprocedural bleeding and allowed completion of the endoscopic resection procedure.

Another important feature of PuraStat is the stability of the gel coat that is formed on the mucosal surface of the GI tract. PuraStat is comprised of three different types of amino acids (arginine, alanine, and aspartic acid) that form the peptide RADA16, which upon contact with physiological fluid assembles into nano fibers that form a three-dimensional extracellular matrix-like structure. Such an extracellular matrix-like structure is likely to be responsible for, on one hand, more stable adhesion of the gel to the mucosal surface thereby prolonging the hemostatic effect and, on the other hand, the hypothesized enhancement of the mucosal repair process [17].

Recent studies have highlighted the efficacy of PuraStat in reducing the rate of post-procedural bleeding in patients un-

dergoing EMR and ESD when applied prophylactically over the resection base. Subramanian et al. [14] reported a delayed bleeding rate of 3% in a case series of 100 patients in whom PuraStat was applied after an endoscopic resection; the authors suggested that, despite the lack of a matched control group, the bleeding rate could be considered lower than that anticipated in such a high risk group of patients, whose mean lesion size was 3.7 cm, with 30% of them on antithrombotic therapy. Similar results have been achieved in smaller studies of patients with a high risk of delayed bleeding, with a post-procedural bleeding rate of 6.2% [17].

The stability of the extracellular matrix-like structure of PuraStat could possibly also explain its efficacy in stopping spurting bleeding. Three of six patients with spurting bleeding in the Subramanian series had their bleeding successfully stopped by PuraStat [14]. In our series 6/13 spurting bleeds were stopped; in five of the remaining seven patients, PuraStat was able to slow the bleeding and enhance the efficacy of further hemostatic methods.

Furthermore, we successfully treated a pancreatic cystic hemorrhage by applying PuraStat through the stent into the cavity. This presentation represents the first description of the use of a topical therapy to manage a pseudocyst hemorrhage and is likely to be a further demonstration of the efficacy of the product in managing arteriolar bleeding.

In our study, PuraStat was reported to be very easy and safe to use. We did not register any adverse events related to the product. PuraStat is available in single prefilled and ready-to-use syringes that require no preparation, and its delivery occurs through a fine catheter introduced through the biopsy channel of the endoscope. We were able to apply PuraStat very easily and quickly in all patients without any technical challenges related to its preparation, catheter clogging, or visual obscuration. These features are likely to be very important when treating a gastrointestinal bleed (► **Video 1**).

Our study does have limitations, mainly owing to its retrospective nature and the lack of a control group, but also to the heterogeneity of the patient cohort and of the treated lesions. Regarding the first two points, we clearly defined the indications for PuraStat prior to starting to use it in our hospitals: according to the current guidelines [1], we have used PuraStat as a rescue therapy after the failure of at least two other hemostatic techniques. Moreover, the endoscopists involved are all experts in the management of bleeding and in the use of the different hemostatic methods, so the overuse of PuraStat was unlikely.

Regarding the third point, our study aims were to describe the real-life use of PuraStat in three tertiary endoscopy centers and provide new data on its efficacy, when other methods have failed, in different clinical scenarios, various AGIB sources, and differing anatomical locations. The data currently available on the hemostatic efficacy of PuraStat in the management of AGIB are sparse and concern mainly its use as a primary therapy in patients undergoing endoscopic resection [14–17]. In the future, our data could be used to design further prospective randomized studies, with the aim of defining the role of PuraStat in the management of difficult AGIB.

In conclusion, our data suggest that PuraStat is a reliable, safe, and effective agent in the management of AGIB. It can be applied very quickly and without any complications, and its presence on the mucosa does not hinder the application of further hemostatic methods. We suggest its use in difficult bleeding when conventional hemostatic methods have failed, but further data are needed to define more precisely its place in the therapeutic flowchart of different AGIBs.

## Competing interests

The authors declare that they have no conflict of interest.

## References

- [1] Gralnek IM, Dumonceau JM, Kuipers EJ et al. Diagnosis and management of nonvariceal upper gastrointestinal hemorrhage: European Society of Gastrointestinal Endoscopy (ESGE) Guideline. *Endoscopy* 2015; 47: a1–a46
- [2] Cook DJ, Guyatt GH, Salena BJ et al. Endoscopic therapy for acute nonvariceal upper gastrointestinal hemorrhage: a meta-analysis. *Gastroenterology* 1992; 102: 139–148
- [3] Mourad FH, Leong RW. Role of hemostatic powders in the management of lower gastrointestinal bleeding: A review. *J Gastroenterol Hepatol* 2018; 33: 1445–1453
- [4] Sung JJ, Luo D, Wu JC et al. Early clinical experience of the safety and effectiveness of Hemospray in achieving hemostasis in patients with acute peptic ulcer bleeding. *Endoscopy* 2011; 43: 291–295
- [5] Huang R, Pan Y, Hui N et al. Polysaccharide hemostatic system for hemostasis management in colorectal endoscopic mucosal resection. *Dig Endosc* 2014; 26: 63–68
- [6] Karaman A, Baskol M, GURSOY S et al. Endoscopic topical application of Ankaferd Blood Stopper in gastrointestinal bleeding. *J Altern Complement Med* 2012; 18: 65–68
- [7] Cahyadi O, Bauder M, Meier B et al. Effectiveness of TC-325 (Hemospray) for treatment of diffuse or refractory upper gastrointestinal bleeding – a single centre experience. *Endosc Int Open* 2017; 5: E1159–E1164
- [8] Chen YI, Barkun A, Nolan S. Hemostatic powder TC-325 in the management of upper and lower gastrointestinal bleeding: a two-year experience at a single institution. *Endoscopy* 2015; 47: 167–171
- [9] Prei JC, Barmeyer C, Burgel N et al. EndoClot polysaccharide hemostatic system in nonvariceal gastrointestinal bleeding: Results of a prospective multicenter observational pilot study. *J Clin Gastroenterol* 2016; 50: e95–e100
- [10] Matsumura K, Nakajima N, Sugai H et al. Self-degradation of tissue adhesive based on oxidized dextran and poly-L-lysine. *Carbohydr Polym* 2014; 113: 32–38
- [11] Luo Z, Wang S, Zhang S. Fabrication of self-assembling d-form peptide nanofiber scaffold d-EAK16 for rapid hemostasis. *Biomaterials* 2011; 32: 2013–2020
- [12] Song H, Zhang L, Zhao X. Hemostatic efficacy of biological self-assembling peptide nanofibers in a rat kidney model. *Macromol Biosci* 2010; 10: 33–39
- [13] Masuhara H, Fujii T, Watanabe Y et al. Novel infectious agent-free hemostatic material (TDM-621) in cardiovascular surgery. *Ann Thorac Cardiovasc Surg Methods Enzymol* 2012; 18: 444–451
- [14] Subramaniam S, Kandiah K, Thayalasekaran S et al. Haemostasis and prevention of bleeding related to ER: The role of a novel self-assembling peptide. *United European Gastroenterol J* 2019; 7: 155–162
- [15] Yoshida M, Goto N, Kawaguchi M et al. Initial clinical trial of a novel hemostat, TDM-621, in the endoscopic treatments of the gastric tumors. *J Gastroenterol Hepatol* 2014; 29: (Suppl. 04): 77–79
- [16] Uraoka T, Ochiai Y, Fujimoto A et al. A novel fully synthetic and self-assembled peptide solution for endoscopic submucosal dissection-induced ulcer in the stomach. *Gastrointest Endosc* 2016; 83: 1259–1264
- [17] Pioche M, Camus M, Rivory J et al. A self-assembling matrix-forming gel can be easily and safely applied to prevent delayed bleeding after ERs. *Endosc Int Open* 2016; 4: E415–E419
- [18] Yau AH, Ou G, Galorport C et al. Safety and efficacy of Hemospray(R) in upper gastrointestinal bleeding. *Can J Gastroenterol Hepatol* 2014; 28: 72–76
- [19] Chen YI, Barkun A, Nolan S. Hemostatic powder TC-325 in the management of upper and lower gastrointestinal bleeding: a two-year experience at a single institution. *Endoscopy* 2015; 47: 167–171
- [20] Sulz MC, Frei R, Meyenberger C et al. Routine use of Hemospray for gastrointestinal bleeding: prospective two-center experience in Switzerland. *Endoscopy* 2014; 46: 619–624
- [21] Smith LA, Stanley AJ, Bergman JJ et al. Hemospray application in non-variceal upper gastrointestinal bleeding: results of the Survey to Evaluate the Application of Hemospray in the Luminal Tract. *J Clin Gastroenterol* 2014; 48: e89–e92
- [22] Haddara S, Jacques J, Leclaire S et al. A novel hemostatic powder for upper gastrointestinal bleeding: a multicenter study (the "GRAPHE" registry). *Endoscopy* 2016; 48: 1084–1095